

Research Article

# The clinicopathological correlates of Cystoisosporiasis in immunocompetent, immunocompromised and HIV-infected/AIDS patients, but neglected in SARS-CoV-2/COVID-19 patients?

Chrysanthus Chukwuma Sr\*

The Chrysanthus Centre for Future-Oriented Studies, Abakaliki, Ebonyi State, Nigeria

## Abstract

Cystoisosporiasis (formerly isosporiasis) is caused by *Cystoisospora belli* (erstwhile named *Isospora belli*) is encountered globally, particularly in tropical and subtropical regions. Cystoisosporiasis is a human intestinal disease whose etiology is the parasite *Cystoisospora belli* with infection frequent in immunocompromised subjects, principally HIV-infected and AIDS patients. This coccidium parasite infects the epithelial cells and lining of the villi of the small and large intestines. *C. belli* is the least frequent of the three intestinal coccidia, viz: *Cryptosporidium*, *microsporidium* and *C. belli* which perturb humans. The clinical presentation of cystoisosporiasis gives a semblance of inflammatory bowel disease and irritable bowel syndrome, as well as other gastrointestinal symptoms, nausea, vomiting and diarrhoea found in COVID-19, AIDS and HIV-infected patients. Research has not presented comorbid features of COVID-19 and cystoisosporiasis. The oocytes of *C. belli* are visualizable microscopically on wet mounts via bright-field, differential interference contrast (DIC) and epifluorescence. Trimethoprim sulfamethoxazole constitute the normal treatment of choice. *C. belli*, HIV-infected/AIDS and COVID-19 patients have clinicopathological correlates necessary to elucidate comorbidities and mechanisms of the diseases.

## Introduction

Cystoisosporiasis, erstwhile recognized as isosporiasis constitutes an unusual diarrhoeal morbidity due to the protozoan, *Cystoisospora belli*, previously identified as *Isosporabelli*. *Cystoisospora belli* is the sole species of the genus *Cystoisospora*. In 1860 [1,2], Virchow initially established it as such. The genus *Cystoisospora* has ardent relationship with *Cyclospora*, *Cryptosporidium* and *Toxoplasma*. However, Cystoisosporiasis infection seldom occurs in comparison to the latter two. The index case was in 1915 [1,2]. *Cystoisospora* undergoes maturation in enterocytes, and are passed through faeces, and transmitted via faecal-oral route from intake of contaminated or polluted food or water, as well as direct contact with *cystoisospora*-infected objects,

immunocompromised and immunocompetent persons [3]. There is no extant veritable treatment for *Cystoisospora* infections in immunocompromised entities, such as HIV/AIDS infected individuals [4]; thus, paving the trajectory for epidemiological elucidation and strategy for prevention and effective control of the transmission and dissemination of the disease and parasite as well as *Cryptosporidium* [5,6] and *Microsporidium* [7] in HIV-positive and AIDS patients. The probable comorbidity of cystoisosporiasis and the novel coronavirus has perspicuously been neglected in the current pandemic studies of COVID-19. The presenting clinicopathological correlates in *C. Belli*, HIV-infected/AIDS and COVID-19 patients are pertinent features to differentiate, explicate and control these infections in the community.

## More Information

### \*Address for Correspondence:

Dr. Chrysanthus Chukwuma Sr, The Chrysanthus Centre for Future-Oriented Studies, Abakaliki, Ebonyi State, Nigeria, Tel: +2347058795062; Email: cfos\_nigeria@yahoo.com; Chrysanthus\_chukwuma@yahoo.com

Submitted: December 22, 2020

Approved: January 19, 2021

Published: January 20, 2021

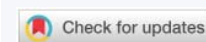
### How to cite this article:

Chukwuma C. The clinicopathological correlates of Cystoisosporiasis in immunocompetent, immunocompromised and HIV-infected/AIDS patients, but neglected in SARS-CoV-2/COVID-19 patients? Int J Clin Microbiol Biochem Technol. 2021; 4: 001-004.

DOI: 10.29328/journal.ijcmbt.1001018

Copyright: © 2021 Chukwuma C. This is an open access article distributed under the Creative Commons Attribution License, which permits unrestricted use, distribution, and reproduction in any medium, provided the original work is properly cited.

Keywords: *Cystoisospora belli*; HIV; AIDS; Inflammatory bowel syndrome; Diarrhoea





## Life history

*C. belli* is a protozoan parasite of the Phylum Apicomplexa. The coccidium has subcellular organelles and a life cycle with both sexual and asexual stages in a single host; and ostensibly contributes to an appreciable percentage of persistent and fulminating diarrhoea in HIV/AIDS patients globally. *C. belli* infects Man through the ingestion of sporulated oocytes in contaminated or polluted water or food. The sporulated oocytes are capable of surviving in the internal or external milieu for prolonged period. Endogenous stages of *C. belli* constitute multinucleated asexual stages (schizonts), uninucleated asexual stages (merozoites), ovum-like stage/female sexual stages (macrogamonts), male sexual stages/sperm-like stages (microgamonts) and oocytes which are produced through fertilization of a macrogamont. The endogenous stages occur in vacuoles within erythrocytes lining the villi of small and large intestines [8]; and seldom in the epithelium of bile duct [9]. Certain merozoites are detectable in the lamina propria [10], with probable resultant intestinal infestations. Monozoic cysts have been detected in the lamina propria of AIDS patients; and intestinal infections with tissue cyst-like stages have perspicuously occurred in mesenteric, periaortic and mediastinal lymph nodes, liver and spleen of AIDS patients [11], and ostensibly in immunocompetent patients, where they are dormant representatives of the infestation with solitary merozoite stages. These are ostensibly implicated in resurgences observed in several patients [12].

## Epidemiology

The *Cystoisospora belli* parasites which are commonly detected in HIV-infected and AIDS subjects in tropical and subtropical environments constitute circa 20% of diarrhoeal episodes or events in these patients [13]. However, among the three coccidia *Cryptosporidium* [5,6], *microsporidium* [7] and *Cystoisospora*, the latter is the least deleterious. A paramount issue in HIV/AIDS is diarrhoea due to opportunistic intestinal protozoa, such as *Cystoisospora belli*. An estimated pooled prevalence for *Cystoisospora* of 2.5% (788/105,922; 95% CI: 2.1% - 2.9%), with a high prevalence of infection has been realised in sub-Saharan Africa as well as a global high prevalence in patients presenting with diarrhoea [14]. An estimated 90% of HIV-infected and AIDS patients in LMICs, and 30% - 60% in high income countries present with diarrhoea [15]. Conversely, ecological analysis [16] show that temperate or high-income regions mostly present with an elevated rate of the novel coronavirus infection. *C. belli* infection is accompanied by diminished quality of life and worse prognosis for HIV/AIDS patients [17]. Also, evident are adverse diarrhoea in similar immunocompromised individuals and acute self-limiting excoriating cachexia and mortality in AIDS [18].

## Clinicopathological characteristics

Usually, protozoal infections are not implicated in the

etiology of peripheral or tissue eosinophilia, but *C. belli* infection constitutes an exception in this clinicopathologic instance [19]. *C. belli* infection in immunocompetent hosts precipitates into a self-limited diarrhoea with duration of 2-3 weeks. In HIV-infected and AIDS patients with CD4 counts < 200 cells/mm<sup>3</sup> not on TMP/SMX prophylaxis, it presents as severe, debilitating and protracted diarrhoea sometimes accompanied by anorexia, cachexia, fatigue, fever, nausea and vomiting [20]. Other clinical manifestations include profuse, watery, non-bloody diarrhoea, and odoriferous flatus, cramping abdominal pain, mimics inflammatory bowel disease and irritable bowel syndrome, less frequent vomiting that is seldom accompanied by nausea, low-grade fever, steatorrhea in protracted cases, seldom presentations of headache and myalgia, while diarrhoea is the most debilitating sequelae, especially in young or immunoincapacitated patients [21, 22]. On the other hand, young persons are generally spared in SARS-CoV-2/COVID-19 infections [16].

## Gall bladder perturbation

Cystoisosporiasis is a gallbladder infection that has not been given due cognizance in immunocompetent hosts due to surreptitious histopathologic findings and low index of uncertainty during routine examination of cholecystectomy specimens. It is crucial to detect the *Cystoisospora belli* in order to elucidate the life cycle and to be informed of its clinicopathological characteristics in immunocompromised victims [23] as in HIV-infected and AIDS patients. Cholecystectomy indications have remarkably altered as *Cystoisospora belli* has continuously been reported in immunocompetent patients. The residence prevalence and clinical association of *C. belli* in the gallbladder presented a latent status with a commensal predisposition [24].

## Diagnosis

The clinical presentation of cystoisosporiasis mimics cryptosporidiosis; thus, necessitating microscopic detection of stool sample or biopsy of the intestinal wall for differentiation and diagnostic confirmation or certainty [25]. The diagnosis is confirmed via oocyte identification in wet preparations or the application of modified acid fast stain. Where the stool examination is negative, it is pertinent to perform intestinal biopsy or duodenal aspirates for the identification of *C. belli*. The common diagnostic stage is the immature oocyte having a spherical protoplasm mass. Oocytes present as ellipsoids of 20-30um in length and 10-19um in width. A mature oocyte constitutes two sporocysts with four sporozoites [20].

Persistent diarrhoea of duration at least fourteen days is characteristically caused by bacteria or parasites, such as *Cryptosporidium* [5], and less commonly by *Cystoisospora belli*. Another testing procedure involves the multiplex polymerase chain reaction (PCR), a simultaneous single test identifying unique DNA sequences for detecting a consortium of diarrhoeal etiologies [26]. It necessitates accurate diagnosis to ascertain the proper treatment regimen.



## Treatment

The veritable treatment regimen for cystoisosporidiasis includes TMP/SMX as duly prescribed contextually, or pyrimethamine and leucovorin in combination or disparately with ciprofloxacin or other fluoroquinolones or nitazoxanide in immunocompetent hosts. In immunosuppressed patients, such as HIV-infected or AIDS subjects, it is advisable to consume TMP/SMX concomitantly with antiretroviral regimen [20].

## Discussion

Cystoisosporiasis and certain other protozoa constitute emerging and re-emerging infectious diseases [27]. Cystoisosporiasis is restrictively a human parasitosis located principally in the subtropics and tropics of low- and middle-income countries, LMICs than in high-income countries. The etiologic agent is *Cystoisospora belli* that infects Man through the ingestion of contaminated food or water containing the protozoon. In immunocompetent individuals, it is frequently self-limiting, asymptomatic or may present fever, diarrhoea and other symptoms. Conversely, in HIV-infected and AIDS patients, it presents severe symptomatic morbidity and clinicopathologic course. Also, COVID-19 patients present fever, gastrointestinal symptoms, such as diarrhoea, nausea and vomiting [28]. The work on Cystoisosporiasis must focus on target-based drug leads, discovery and development [29, 30].

## Conclusion

It is not probable that cystoisosporiasis patients are more susceptible to COVID-19/SARS-CoV-2 since there are absolutely no extant data to undergird such instance. However, the novel coronavirus alterations have diminished the capacity to deliver care.

The epidemiology and clinicopathologic attributes of *C. belli* undergird the significance of routine surveillance for the protozoon parasite in HIV-positive and AIDS patients as well as other immunosuppressed patients in vulnerable populations for the development of public policy, healthcare administration and delivery including optimum clinical settings and services locally and globally for sustainable development.

## References

1. Woodcock HM. Notes on protozoan parasites in the excreta. *BMJ*. 1915; 2: 709.
2. Minnaganti VR, Talavera F, Kong JW, Bronze MS, Lessnau KD, et al. Cystoisosporiasis: clinical presentation. *Medscape*. 2018. <https://emedicine.medscape.com/article/219776-clinical>
3. Pape JW, Johnson WD Jr. *Isospora belli* infections. *Prog Clin Parasitol*. 1991; 2: 119-127.   
**PubMed:** <https://pubmed.ncbi.nlm.nih.gov/1893117/>
4. Miao YM, Gazzard BG. Management of protozoal diarrhoea in HIV disease. *HIV Med*. 2000; 1: 194-199.   
**PubMed:** <https://pubmed.ncbi.nlm.nih.gov/11737348/>
5. Chukwuma Sr C. Cryptosporidium: Still a public health problem: A review. *Niger Med J*. 1996; 30: 6-10.
6. Chukwuma Sr C. Cryptosporidium: Public health problems and environmental indicators. *Austin Med Sci*. 2019; 4: 1036.   
[ams-v4-id1036.pdf](https://pubmed.ncbi.nlm.nih.gov/3211036/)
7. Chukwuma Sr C. Microsporidium in AIDS patients: A perspective. *East Afr Med J*. 1996; 73: 72-75.   
**PubMed:** <https://pubmed.ncbi.nlm.nih.gov/8625869/>
8. Trier JS, Moxey PC, Schimmel EM, Robles E. Chronic intestinal coccidiosis in man, intestinal morphology and response to treatment. *Gastroenterology*. 1974; 66: 923-935.   
**PubMed:** <https://pubmed.ncbi.nlm.nih.gov/4826994/>
9. Benator DA, French AL, Beaudet LM, Levy CS, Orenstein JM. *Isospora belli* infection associated with acalculous cholecystitis in a patient with AIDS. *Am Int Med*. 1994; 121: 663-664.   
**PubMed:** <https://pubmed.ncbi.nlm.nih.gov/7944075/>
10. Velasquez JN, Carnevale S, Mariane M, Kuo LH, Caballero A, et al. Isosporosis and unizuite tissue cysts in patients with acquired immunodeficiency syndrome. *Hum Pathol*. 2001; 32: 500-505.   
**PubMed:** <https://pubmed.ncbi.nlm.nih.gov/11381368/>
11. Lindsay DS, Dubey JP, Toivio-Kinnucan MA, Michiels JF, Blagburn BL. Examination of extra-intestinal tissue cysts of *Isospora belli*. *J Parasitol*. 1997; 83: 620-625.   
**PubMed:** <https://pubmed.ncbi.nlm.nih.gov/9267401/>
12. Lindsay DS, Weiss LM. *Isospora belli*. *Antimicrobe*. 2017. [www.antimicrobe.org/b04rev.asp](http://www.antimicrobe.org/b04rev.asp)
13. Marcos LA, Gotuzzo E. Intestinal protozoan infections in the immune compromised host. *Curr Opin Infect Dis*. 2013; 26: 295-301.   
**PubMed:** <https://pubmed.ncbi.nlm.nih.gov/23806893/>
14. Wang ZD, Liu Q, Liu HH, Li S, Li Z, et al. Prevalence of Cryptosporidium, microsporidia and isospora infection in HIV-infected people: a global systematic review and meta-analysis. *Parasites Vectors*. 2018; 11: 28.   
**PubMed:** <https://pubmed.ncbi.nlm.nih.gov/29316950/>
15. Shimelis T, Tassachew Y, Lambiyo T. Cryptosporidium and other intestinal parasitic infections among HIV patients in southern Ethiopia: significance of improved HIV-related care. *Parasit Vectors*. 2016; 9: 270.   
**PubMed:** <https://www.ncbi.nlm.nih.gov/pmc/articles/PMC4862162/>
16. Chukwuma Sr C. Ecological analysis of the COVID-19 pandemic for restoration and sustainability. *Research and Advances in Pharmacy and Life Sciences*. 2020; 3.
17. Logan C, Beadsworth MB, Beeching NJ. HIV and diarrhoea. What is new? *Curr Opin Infect Dis*. 2016; 29: 486-494.   
**PubMed:** <https://pubmed.ncbi.nlm.nih.gov/27472290/>
18. Taye B, Desta K, Ejigu S, Dori GU. The magnitude and risk factors of intestinal parasitic infection in relation to human immunodeficiency virus infection and immune status, at ALERT Hospital, Addis Ababa, Ethiopia. *Parasitol Int*. 2014; 63: 550-556.   
**PubMed:** <https://pubmed.ncbi.nlm.nih.gov/24603288/>
19. Goodgame RW. Understanding intestinal spore-forming protozoa: Cryptosporidia, microsporidia, isospora, and cyclospora. *Ann Intern Med*. 1996; 124: 429-441.   
**PubMed:** <https://pubmed.ncbi.nlm.nih.gov/8554253/>
20. Kizilbash QF, Horvath L. Diarrhea in a patient with pulmonary tuberculosis. *Gastroenterology*. 2016; 151: e12-13.   
**PubMed:** <https://pubmed.ncbi.nlm.nih.gov/27591425/>
21. Batista FS, L de Souza Miranda, MB de Oliveira Silva, Lafontaine R, Taborda M, et al. Chronic *Cystoisospora belli* infection in an HIV/AIDS patient treated at the specialized assistance service in Porto Velho County - Rondonia. *Rev Soc Bras Med Trop*. 2019; 52: e20180204.   
**PubMed:** <https://pubmed.ncbi.nlm.nih.gov/31141043/>
22. Tiryaki TO, Anil KU, Buyuk M, Yildirim AY, Atasoy A, et al. Prolonged, severe watery diarrhea in long-term myeloma survivor: An unforeseen



- infection with *Isospora belli*. *Turk J Haematol.* 2020; 10: 28.  
**PubMed:** <https://pubmed.ncbi.nlm.nih.gov/33112100/>
23. Fazio R, Waintraub D, Rahmani R, Hajdu C, Park JS. 1256 *Cystoisospora belli* infection of the gallbladder: More common than you may think. *Am J Gastroenterol.* 2019; 14: 5698-S700.
24. Noor M, Katzman PJ, Huber AR, Findeis-Hosey JJ, Whitney-Miller C, et al. Unexpectedly high prevalence of *Cystoisospora belli* infection in acalculous gallbladders of immunocompetent patients. *Am J Clin Pathol.* 2019; 151: 100-107.  
**PubMed:** <https://pubmed.ncbi.nlm.nih.gov/30285068/>
25. Myhre J, Sifris D. Cystoisosporiasis (isosporiasis) symptoms and treatment. 2020.  
<https://www.verywellhealth.com/cystoisosporiasis-isosporiasis-48977>
26. DuPont HL. Persistent diarrhea: A clinical review. *JAMA.* 2016; 315: 2712-2723.  
**PubMed:** <https://pubmed.ncbi.nlm.nih.gov/27357241/>
27. Chukwuma Sr C. Bioinformatics-base and determinants in the spatiotemporal variations of emerging and reemerging infectious diseases. *J Ancient Dis Prevent Remedies.* 2018; 06.
28. Larsen JN, Martin MB, Martin JD, Kuhn P, Hicks JB. Modeling the onset of symptoms of COVID-19. *Front Public Health.* 2020; 8: 473.  
**PubMed:** <https://pubmed.ncbi.nlm.nih.gov/32903584/>
29. Chukwuma Sr C. Probing research precincts focused on systematic determination of the biological effects of macromolecular interactions. *Int J Applied Sci Engineering Rev.* 2020; 1.
30. Chukwuma Sr C. Metabolic co-regulation of protein and nucleic acid interactions in fungi and bacteria. *Mat Journals. J Adv Pharm Practi.* 2020; 2: 41-51.